

Case Report

Persistent left superior vena cava: a case report and review of literature

Sirin Mneimneh*, Ahmad Shatila, Ghassan Shehab, Mariam Rajab

Department of Pediatrics, Makassed General Hospital, Beirut, Lebanon

Received: 20 October 2014

Revised: 28 October 2014

Accepted: 12 November 2014

***Correspondence:**

Dr. Sirin Mneimneh,

E-mail: sirin.mneimneh@gmail.com

Copyright: © the author(s), publisher and licensee Medip Academy. This is an open-access article distributed under the terms of the Creative Commons Attribution Non-Commercial License, which permits unrestricted non-commercial use, distribution, and reproduction in any medium, provided the original work is properly cited.

ABSTRACT

Persistent Left Superior Vena Cava (PLSVC) is rare but important congenital vascular anomaly. It results when the left superior cardinal vein caudal to the innominate vein fails to regress. It is most commonly observed in isolation but can be associated with other cardiovascular abnormalities. The presence of PLSVC can render access to the right side of heart challenging via the left subclavian approach, which is a common site of access utilized. Incidental notation of a dilated coronary sinus on echocardiography should raise the suspicion of PLSVC. Here we present a case of PLSVC that was discovered in an infant accidentally after central line insertion.

Keywords: Persistent left superior vena cava (PLSVC), Central line

INTRODUCTION

Central venous access device placement is a common place practice for many physicians, including surgeons, interventional radiologists, and other physicians.¹ Successful placement of such central venous access devices can sometimes be very challenging. Therefore, having a thorough understanding of venous anatomy, including the recognition of congenital venous anomalies and having a good working knowledge of alternative and supplemental strategies for placement of central venous access devices, are critical factors to maximizing the success of device placement and to minimizing the risk of potential complications.¹

Persistent Left Superior Vena Cava (PLSVC) is an uncommon vascular anomaly. It is usually asymptomatic and is detected when cardiovascular imaging is performed for unrelated reasons. When a left subclavian approach is used for vascular access, its presence can complicate catheter placement within the right side of heart. Here we present a case that highlights the practical implications PLSVC. Further, we provide insight into the

embryonic basis of this anomaly and we review a diagnostic approach.

CASE REPORT

A 1-month old female baby, born by normal vaginal delivery at term to primi mother, was referred to our neonatal intensive care unit with 2 weeks history of vomiting, diarrhea, associated with decrease po intake, hypoactivity and decrease urine output.

On admission, the girl weighed 2415 g (10th percentile), her birth weight was 2970 gm (50th percentile). Patient was tachycardic, she had signs of dehydration: depressed anterior fontanel, sunken eyes, dry mucous membranes, tenting skin turgor otherwise physical examination was unremarkable.

Patient started on IV fluids, investigations started to determine the cause of persistent diarrhea that showed positive IgE specific response to milk protein and patient started on free aminoacids based formula, few days later patient started to develop lower extremities edema,

albumin at that time was 1.96 mg/dl (was 2.8 mg/dl upon admission)

Decision was taken to insert a central line through left internal jugular vein to start total parenteral nutrition.

On routine post-procedural X-ray, an unusual course of the catheter was identified (Figure 1).

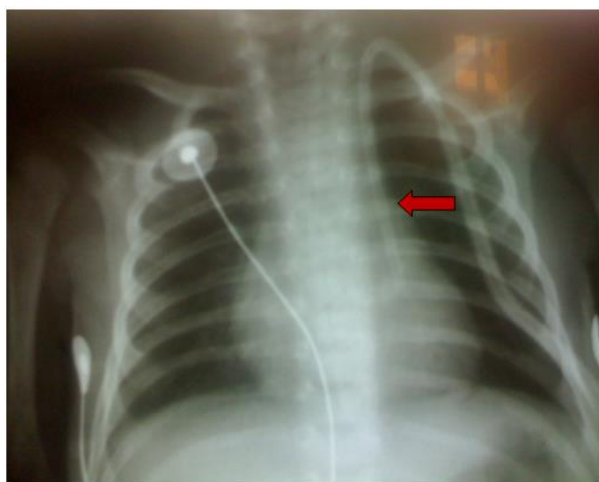

Figure 1: On routine post-procedural X-ray, an unusual course of the catheter was identified.

Persistent left superior vena cava was suspected, and a follow-up echocardiogram showed an abnormal position of the catheter into the coronary sinus through the left superior vena cava, with no associated structural heart anomalies.

DISCUSSION

A persistent left superior vena cava is seen in 0.3%-0.5% of the normal population^{2,3} and 4.5% in individuals with congenital heart disease.⁴

Development of persistent LSVC

The major venous system of the embryo is composed of two pairs of cardinal veins; the anterior cardinal veins, which drain cranial parts and the posterior cardinal veins, which drain caudal parts. Both pairs of cardinal veins drain into the embryonic heart via the right and left common cardinal veins. During the 8th week of gestation the innominate vein connects the left and right anterior cardinal veins. The cephalic portions of the anterior cardinal veins form the internal jugular veins while the caudal portions of the right anterior and a part of the corresponding common cardinal vein form the normal right-sided superior vena cava. The left anterior cardinal vein, caudal to the innominate vein, obliterates to form “the ligament of Marshall”, which was described in 1850 as a “vestigial fold of pericardium”.⁵ The left common cardinal vein normally persists as coronary sinus and oblique vein. The LSVC is a congenital malformation

and represents the persistence of the left anterior cardinal vein⁶ that continues into the left sinus horn (left duct of Cuvier) during the early developmental period. Figure 2 is a schematic representation of the developmental anatomy of the heart.

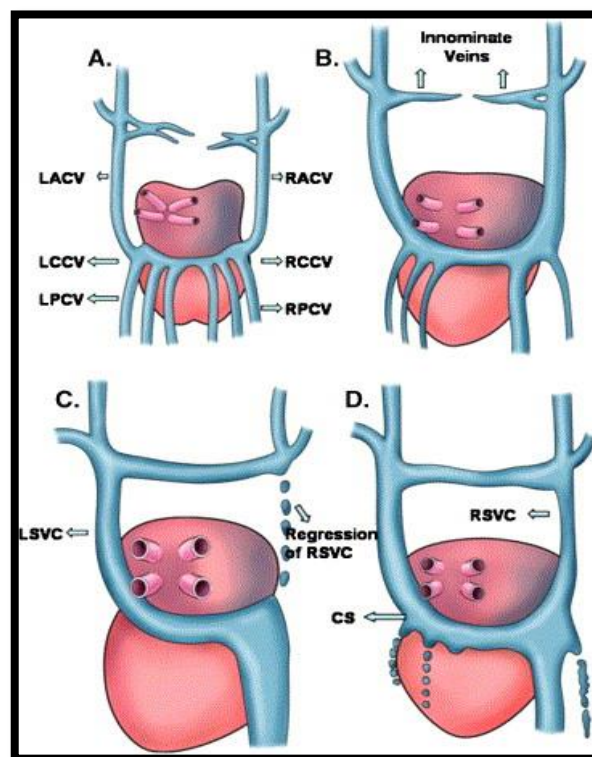


Figure 2: Developmental anatomy of the persistent left superior vena cava as viewed from the posterior aspect of the heart. A: Pairs of anterior and posterior cardinal veins draining into the embryonic heart via the right and left common cardinal veins. B: Development of bridging innominate vein connecting left and right anterior cardinal veins during 8th week of gestation. C: Regression of the right-sided superior vena cava with persistence of left-sided superior vena cava as a single superior vena cava that drains the cephalic portion of the body including upper extremities. D: Right-sided superior vena cava connected with the persistent left superior vena cava via innominate vein in the post-natal heart.

Abbreviations: CS: coronary sinus, LACV: left anterior cardinal vein, LCCV: left common cardinal vein, LPCV: left posterior cardinal vein, LSVC: left superior vena cava, RACV: right anterior cardinal vein, RCCV: right common cardinal vein, RPCV: right posterior cardinal vein, RSVC: right superior vena cava.

In the most common form of PLSVC, both the left and right SVCs are present. A bridging innominate vein may or may not be present. Less frequently, the caudal right superior cardinal vein regresses resulting in absent right SVC with PLSVC (isolated PLSVC), with a reported incidence of 0.1%.⁷

The presence of isolated PLSVC is associated with various clinical problems,⁸ such as rhythm abnormalities (atrioventricular block because of stretching of the atrioventricular node and His bundle secondary to dilatation of the coronary sinus), a high incidence of accompanying congenital heart defects.⁹ (ventricular and atrial septal defects), and the inability to insert central venous catheters and transvenous leads through the right internal jugular/subclavian vein. Suspicion of LSVC may arise on the posteroanterior chest x-ray, where it may appear as widening of aortic shadow, paramediastinal bulging, paramedian stripe, or a low-density line along upper left margin of the heart.¹⁰ Placement of catheter via left subclavian approach demonstrates an unusual course of catheter on chest X-ray, a dilated coronary sinus (>1 cm) on echocardiography, raise suspicion of anomaly.

The echocardiographic evaluation should be followed by agitated saline application from the left or right arm. Normally, the infusion of saline injection from the left or right antecubital vein results in opacification of the right atrium. In cases where the right SVC accompanies the PLSVC, contrast given from the left arm first appears in the coronary sinus, whereas contrast given from the right arm first appears in the right atrium.

Other imaging modalities, like venous computed tomography or magnetic resonance imaging, directly visualize the venous anatomy and confirm the diagnosis.¹¹ The technical difficulties associated with persistent LSVC may lead to misplacement of catheter and injury to the vessel wall. Serious complications including angina, arrhythmia, cardiogenic shock, and even cardiac arrest have been reported when a guide wire or catheter is manipulated via persistent LSVC.¹²

Back to our patient, line was removed to avoid the risk of arrhythmia, patient was given once IV albumin and started progressively to tolerate free amino acid based formula, diarrhea stopped and edema markedly improved.

CONCLUSION

Persistence of LSVC should be considered, especially when central venous catheterization via the left subclavian or internal jugular vein proves to be difficult, and the fluoroscopy or chest x-ray suggests an aberrant left-sided course for the catheter.

Funding: No funding sources

Conflict of interest: None declared

Ethical approval: Not required

REFERENCES

1. Pivoski SP. Long-term venous access. In: Pazdur R, Wagman LD, Camphausen KA, Hoskins WJ, eds.

2. Biffi M, Boriani G, Frabetti L, Bronzetti G, Branzi A. Left superior vena cava persistence in patients undergoing pacemaker or cardioverter-defibrillator implantation: a 10-year experience. *Chest*. 2001;120:139-44.
3. Perloff JK. Congenital anomalies of vena caval connection. In: Perloff JK, eds. *The Clinical Recognition of Congenital Heart Disease*. 4th ed. Philadelphia: WB Saunders Company; 1994: 703-714.
4. Buirski G, Jordan SC, Joffe HS, Wilde P. Superior vena caval abnormalities: Their occurrence rate, associated cardiac abnormalities and angiographic classification in a paediatric population with congenital heart disease. *Clin Radiol*. 1986;37:131-8.
5. J. Marshall. On the development of the great anterior veins in man and mammalia: including an account of certain remnants of fetal structure found in the adult, a comparative view of these great veins in the different mammalia, an analysis of their occasional peculiarities in the human subject. *Philos Trans R Soc Lond*. 1850;140:133-69.
6. R. Fraser, J. Dvrkin, R. Rosall, R. Eidem. Left superior vena cava. *Am J Med*. 1962;31:711-4
7. Lenox CC, Zuberbuhler JR, Park SC, Neches WH, Mathews RA, Fricker FJ, et al. Absent right superior vena cava with persistent left superior vena cava: implications and management. *Am J Cardiol*. 1980;45:117-22.
8. Neema PK, Manikandan S, Rathod RC. Absent right superior vena cava and persistent left superior vena cava: the perioperative implications. *Anesth Analg*. 2007;105:40-2.
9. Postema PG, Rammeloo LA, van Litsenburg R, Rothuis EG, Hruđa J. Left superior vena cava in pediatric cardiology associated with extra-cardiac anomalies. *Int J Cardiol*. 2008;123:302-6.
10. Cha EM, Khoury GH. Persistent superior vena cava: Radiologic and clinical significance. *Radiology*. 1972;103:375-81.
11. Ucar O, Pasaoglu L, Cicekcioglu H, Vural M, Kocaoğlu I, Aydoğdu S. et al. Persistent left superior vena cava with absent right superior vena cava: a case report and review of the literature. *Cardiovasc J Afr*. 2010;21:164-6.
12. R. Fraser, J. Dvrkin, R. Rosall, R. Eidem. Left superior vena cava. *Am J Med*. 1962;31:711-4.

DOI: 10.5455/2349-3259.ijct20141106

Cite this article as: Mneimneh S, Shatila A, Shehab G, Rajab M. Persistent left superior vena cava: a case report and review of literature. *Int J Clin Trials* 2014;1:114-6.