

## Research Article

# Colposcopic evaluation of cervical lesions: a prospective study

Vineeta Gupta\*, Archna Tandon, Anuja Nanda, Arti Sharma, Neeta Bansal

Department of Obstetrics and Gynaecology, Shri Guru Ram Rai Institute of Medical and Health Sciences, Dehradun, Uttarakhand, India

**Received:** 24 November 2014

**Accepted:** 29 November 2014

**\*Correspondence:**

Dr. Vineeta Gupta,

E-mail: vineetahims@yahoo.co.in

**Copyright:** © the author(s), publisher and licensee Medip Academy. This is an open-access article distributed under the terms of the Creative Commons Attribution Non-Commercial License, which permits unrestricted non-commercial use, distribution, and reproduction in any medium, provided the original work is properly cited.

### ABSTRACT

**Background:** The present study was undertaken to evaluate the role of colposcopy as a screening and diagnostic tool for cervical cancer and other cervical lesions in high risk women.

**Methods:** All the women included in the study were subjected to colposcopic examination. Colposcopic findings were compared with cytology and histopathological examination. Accuracy of colposcopic examination was calculated by standard statistical methods. Sensitivity, specificity, Positive Predictive Value (PPV) and Negative Predictive Value (NPV) of colposcopic examination was calculated.

**Results:** Three hundred patients underwent colposcopic examination. The overall sensitivity and specificity of colposcopy was 85.85% and 87.65% respectively. Positive predictive value was 75.83% and negative predictive value was 95.38%. The percentage of false negative as well as that of false positive was calculated to be 13.74%. The accuracy of colposcopy was found to be more for high grade lesions as compared to low grade lesions.

**Conclusions:** Colposcopy gives immediate and accurate results and its value as diagnostic modality is undisputed. It should also be considered as a primary screening test for high risk women living in remote areas where women cannot visit the doctor repeatedly as the ideal screening triage cannot be implemented in such situations.

**Keywords:** Colposcopy, Cervical lesions

### INTRODUCTION

Cervical cancer continues to be a leading cause of mortality among women in our country, despite the existing prevention programmes. The role of organized screening programmes by conducting annual Pap smear test is undisputed and has been responsible for decreasing the incidence of cervical cancer in the western countries. But it seems that logistic requirements of these programmes cannot be met with in the developing countries.

The present study was, therefore undertaken to evaluate the role of colposcopy as a screening and diagnostic tool for cervical cancer and other cervical lesions in high risk women.

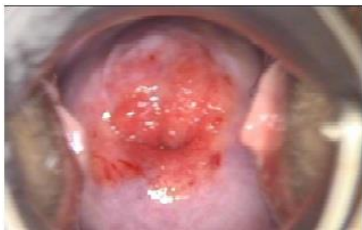### METHODS

The present study was carried out on patients attending the gynaecological OPD of SMI hospital, Dehradun with one or more of the following complaints:

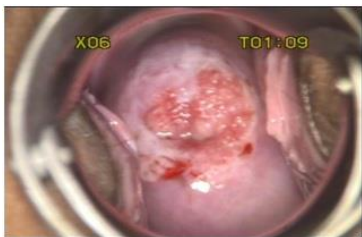1. Women with post coital bleeding, intermenstrual bleeding, persistent vaginal discharge, vulval itching or burning.
2. Women with cervical erosion or unhealthy cervix on per-speculum examination.
3. Women with abnormal cytological (Pap test) findings.

After informed consent, all these women were subjected to colposcopic examination. Colposcopic guided biopsy and or endocervical curettage (ECC) was done whenever indicated on the basis of abnormal colposcopic findings and in patients with abnormal cytology even if colposcopic examination was normal.

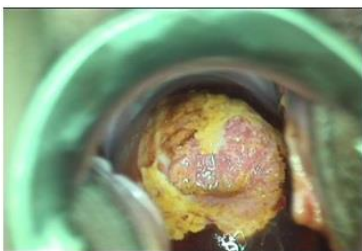
Colposcopic findings were compared with cytology and histopathological examination. Accuracy of colposcopic examination was calculated by standard statistical methods. Sensitivity, specificity, Positive Predictive Value (PPV) and Negative Predictive Value (NPV) of colposcopic examination was calculated.



**Figure 1: Colposcopic visualization of cervix.**



**Figure 2: Cervix after application of acetic acid.**



**Figure 3: Cervix after application of Lugol's iodine.**

**RESULTS**

Three hundred patients, who underwent colposcopic examination, were included in the study. As seen in Table 1, according to the colposcopic examination, 21 patients (7%) had normal findings, 202 (67.33%) had chronic cervicitis, 28 (9.3%) had Low-Grade Squamous Intraepithelial Lesions (LGSIL), 8 (2.6%) had High-Grade Squamous Intraepithelial Lesions (HGSIL), 19 (6.3%) had carcinoma cervix and 17 (5.6%) had senile vaginitis.

Colposcopy was unsatisfactory in 5 (1.6%) patients.

**Table 1: Colposcopy findings (300 patients).**

	No.	%
Normal findings	21	7%
Chronic cervicitis	202	67.33%
LGSIL	28	9.3%
HGSIL	8	2.6%
Ca cervix	19	6.3%
Senile vaginitis	17	5.6%
Unsatisfactory	5	1.6%

Colposcopic guided biopsy was obtained in 104 (34.66%) patients. In 2 of these patients, colposcopy was unsatisfactory. Correlation between colposcopic findings and HPE results was seen in 90 (88.23%) patients and not seen in 12 (11.76%) patients.

Colposcopy was done following cytological examination in 177 (59%) patients. The findings correlated in 160 (90.39%) patients and did not correlate in 15 (8.47%) patients. Colposcopy was unsatisfactory in 2 of these patients.

As seen in Table 2, Sensitivity and specificity of colposcopy for low grade lesions was 76.47% and 77.27% respectively. Positive predictive value was 46.43% and negative predictive value was 92.73%. The percentage of false negative was calculated to be 25.53% and that of false positive was 22.73%.

**Table 2: Statistical comparison of colposcopy for low grade and high grade lesions.**

	Sensitivity	Specificity	PPV	NPV	False -ve	False +ve
Low grade lesions	76.47%	77.27%	46.43%	92.73%	25.53%	22.73%
High grade lesions	95.23%	98.64%	95.23%	98.04%	1.96%	4.76%
Over all results	85.85%	87.65%	75.83%	95.38%	13.74%	13.74%

Sensitivity and specificity of colposcopy for high grade lesions was calculated to be 95.23% and 98.04% whereas the positive predictive value was 95.23% and negative predictive value was 98.04%. The percentage of false

negative was 1.96% and that of false positive was 4.76%. Therefore, accuracy of colposcopy was found to be more for high grade lesions as compared to low grade lesions.

The overall sensitivity and specificity of colposcopy was 85.85% and 87.65% respectively. Positive predictive value was 75.83% and negative predictive value was 95.38%. The percentage of false negative as well as that of false positive was calculated to be 13.74%.

## DISCUSSION

Cervical cancer has an uneven geographic distribution with majority of cases being in the developing countries. Declining trends in the developed countries over the last few decades are attributed to the implementation of organized screening programmes by Pap smear. Colposcopy as a clinical method has been of proven accuracy in evaluating patients with abnormal cervical cytology. But its value as a screening tool has long been disputed.<sup>1</sup>

As effective cytological screening in our country is still not successful, there is a necessity to find other ways to deal with this problem.

In our study, normal finding (including chronic cervicitis and senile vaginitis) were found in 79.83% (240) patients, LGSIL in 9.3% (28) and significant abnormality was found on colposcopic examination in 8.9% (27) patients. In a study by K. Syrjanen et al., during screening colposcopy, normal finding were found in 65.4%, abnormal in 34.6% and significant abnormalities seen in 18.6% patients which is almost comparable to our study.<sup>2</sup>

In another study it was found that CIN lesions and early invasive carcinoma were confirmed in 31.6% by colposcopy as against only 5.4% by cytology alone and the authors concluded that colposcopy should be used as a routine diagnostic modality along with cytology.<sup>3</sup>

In our study, we found that the overall sensitivity and specificity of colposcopy was 85.85% and 87.65% respectively. In a study by N. Sundari, colposcopy had a sensitivity of 84.6% and specificity of 43.4%.<sup>4</sup> The false negative rate was 15.4% and false positive rate 56.4% as compared to 13.74% and 13.74% in our study.<sup>4</sup>

In another study the authors found a positive predictive value of 67.5% in patients with abnormal PAP result and colposcopy directed biopsy. They suggested that colposcopy directed biopsy to be the best choice for evaluation of patients with abnormal Pap result.<sup>5</sup>

On the other hand, Sufang et al. reported that visual inspection and colposcopy should not be used when screening for early stage cervical lesions.<sup>6</sup> In our study also we found accuracy of colposcopy to be more for high grade lesions as compared to low grade lesions. As seen in fig 1a, b & c on naked eye examination cervix appears quite normal but after colposcopy, it looked like cervical cancer, cervical biopsy was obtained and HPE confirmed the diagnosis.

Maria et al found that cytology and colposcopy showed very high sensitivity in detecting CIN and cancer (91.7% and 94.4% respectively) but low specificity (34.6% and 50% respectively). The authors concluded the most efficient combination among tested methodologies was found to be HPV typing with colposcopy.<sup>7</sup>

While colposcopy is critical for further evaluation of abnormal Pap smear, colposcopic findings can be misleading. Due to subjective nature of colposcopy there may be differences in interpretation between observers.<sup>8</sup>

In our series, majority of colposcopies were done by senior colposcopist. This may explain the higher specificity and less false positive rates in our study. However, use of a scoring system such as Reid Index (RCI) may improve the accuracy of colposcopy irrespective of the observer's experience. In a Canadian survey it was found that there was wide variation in management of low-grade cervical lesions among different colposcopists and highlighted the need to establish evidence – based management protocols.<sup>9</sup>

In our country, effective Pap smear screening is still not successful due to logistic reasons and HPV testing is quite costly, age- specific and not always feasible. As seen in our study, colposcopy gives immediate and accurate results and its value as diagnostic modality is undisputed. But it should also be considered as a primary test for high risk women living in remote areas and difficult terrains like Uttarakhand where women cannot visit the doctor repeatedly and the ideal screening triage cannot be implemented in such situations.

*Funding: No funding sources*

*Conflict of interest: None declared*

*Ethical approval: The study was approved by the institutional ethics committee*

## REFERENCES

1. Parham GP, Andrews NR, Loe ML. Comparison of immediate and deferred colposcopy in a cervical screening programme. *Obstet Gynaecol*. 2000;95:340-4.
2. Syrjanen K, Naud P, Derchain S, Roteli-Martins C, Longatto-Filho A, Tatti S, et al. Comparing Pap smear cytology, aided visual inspection, screening colposcopy, cervicography and HCV testing as optional screening tools in Latin America. Study design and baseline data of the LAMS study. *Anticancer Res*. 2005;25:3469-80.
3. Arora R, Vijaya K, Habbeebullah S, Umachigui AO. Colposcopic evaluation of unhealthy cervix. *J Obstet Gynaecol of India*. 2000;50:102-3.
4. Sundari N. Prevalence of CIN in urban population: role of screening colposcopy. *Asian J Obstet Gynaecol Pract*. 2000;4(2):16-9.
5. Farideh D, Nahid A. A comparative study on colposcopy directed biopsy and Pap smear tests in

- patients with an abnormal Pap smear. *Iranian J Pathol*. 2006;1:13-6.
6. Sufang Wu, Li Merg, Shi Xuan Wang, Ding Ma. A comparison of four screening methods for cervical neoplasia. *Int J Gynaecol Obstet*. 2005;91:189-93.
  7. Maria A, Eleni K, Ekatherina C, Dimitirs A, Dimitris H, Christos Y. Comparison of cytology, colposcopy. HPV typing and biomarker analysis in cervical neoplasia. *Anticancer Res*. 2009;29(8):3401-9.
  8. Paul M. Norris, Leo B. Twiggs. Colposcopic grading of cervical intraepithelial neoplasia. *Trends Cervical Health*. 2010;7:1-2.
  9. Nelson GS, Duggan MA, Nation JG. Controversy in colposcopic management: a Canadian survey. *J Obstet Gynaecol Can*. 2006;28(1):36-40.

DOI: 10.5455/2349-3259.ijct20141105

**Cite this article as:** Gupta V, Tandon A, Nanda A, Sharma A, Bansal N. Colposcopic evaluation of cervical lesions: a prospective study. *Int J Clin Trials* 2014;1:110-3.