

Research Article

Use of incus as an interposition graft in ossiculoplasty for type IIb tympanoplasty

Ameya Bihani*, Jyoti Dabholkar

Department of ENT, KEM Hospital, Mumbai, Maharashtra, India

Received: 02 March 2015, **Revised:** 26 March 2015

Accepted: 06 April 2015

*Correspondence:

Dr. Ameya Bihani,

E-mail: ameyabihani87@gmail.com

Copyright: © the author(s), publisher and licensee Medip Academy. This is an open-access article distributed under the terms of the Creative Commons Attribution Non-Commercial License, which permits unrestricted non-commercial use, distribution, and reproduction in any medium, provided the original work is properly cited.

ABSTRACT

Background: In cases of chronic suppurative otitis media, the most common cause for the discontinuity in the ossicular chain is erosion of lenticular or long process of incus. To study hearing results, sequel and complications of using autologous incus as interposition graft in type IIb ossiculoplasty.

Methods: We studied 30 patients who required ossiculoplasty using autologous incus. The pre-operative audiograms were done. Post operatively patients were followed up to 2 years during which complete otological examination with audiogram was done.

Results: According to the American Academy of Otolaryngology-Head and Neck Surgery guidelines, a successful hearing result is the one with post-operative air-bone gap of 20 decibels or less. Hence, by this standard our success rate is 77 percent and in all of our patients we have air-bone gap closure to below 30 decibels. Average closure in air-bone gap (gain) in our patients is 25.9 decibels with average pre-operative and post-operative air-bone gap being 47.70 decibels and 16.9 decibels there was no extrusion of incus. 3 patients had residual perforation and 2 patients had retracted grafts. All the patients with retracted grafts or residual perforation had oedematous middle ear mucosa and Eustachian tube dysfunction and high MER index.

Conclusions: Autologous incus is an excellent interposition graft for ossiculoplasty. There is no risk of transmission of disease and no extra cost involved. Higher values of Middle Ear Risk Index, oedematous middle ear mucosa and Eustachian tube dysfunction are poor prognostic factor for success of ossiculoplasty.

Keywords: Incus, Ossiculoplasty, Type IIb Tympanoplasty

INTRODUCTION

Ossicular chain reconstruction has always been a challenge in surgeries of chronic suppurative Otitis media. In cases of chronic suppurative Otitis media, the most common cause for the discontinuity in the ossicular chain is erosion of lenticular or long process of incus.¹⁻³

In modern era, various different materials are available for ossiculoplasty such as autologous incus, homologous incus, Tragal cartilage, Hydroxyapatite, Titanium, Plastipore, Ceramics, etc. with each having their own merits and demerits, however autologous incus is the

most commonly used material for ossiculoplasty because of having the distinct advantage of easy availability and free of cost.^{1,4,5} It is highly biocompatible, less likely to extrude and with no risk of transmission of diseases. So this study aims at success and sequel of incus as the interposition graft between malleus and stapes in type IIb tympanoplasty.

METHODS

We did an observational prospective study of 30 patients who underwent ossiculoplasty with autologous incus over a span of 2 years.

All the patients who came to ENT-OPD with the complaints of ear discharge or impairment of hearing were assessed clinically (otoscopic examination and tuning fork tests) and by using pure tone audiometry and if needed they were subjected to examination of ear under microscope.

Patients in whom only incus (lenticular process/long process /body) was found necrotized or deformed were taken up for type IIb Tympanoplasty. In such patients, the incus was removed and was held with a clamp to stabilize the body of incus while drilling and reshaping it.

Patient were asked to follow up on day 7, day 28 and day 90 post operatively and subsequent follow up at 6 months and 1 year post operatively. Pre-operative and post-operative clinically finding, pure tone audiograms were compared.

RESULTS

The average age of the patients was 27.83 years with youngest patient of age 8 years and eldest patient was of age of 60 years. Out of 30 patients, 11 were males and 19 were females.

On otoscopy, 22 patients had perforations and 8 patients had retraction pockets.

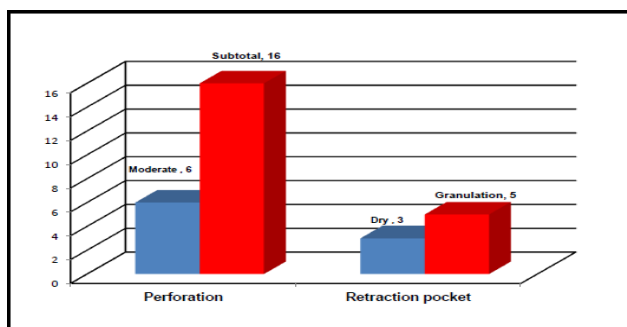


Figure 1: Otoscopic findings.

The preoperative air bone gap varied from 32 decibels to 67 decibels with an average of 45.70 decibels and standard deviation of 9.47 decibels.

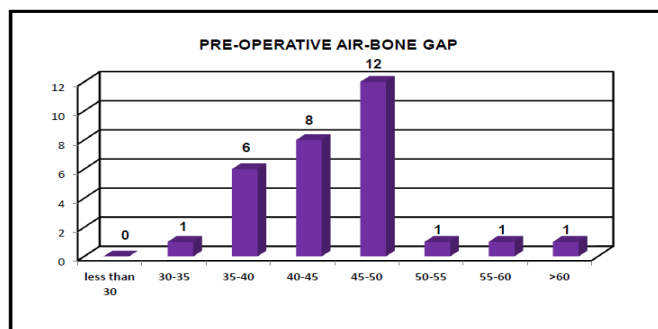


Figure 2: Categorization of patients according to air bone gap.

The post-operative air bone gap varied from 6 decibels to 26 decibels with an average of 16.96 decibels with standard deviation of 7.81 decibels.

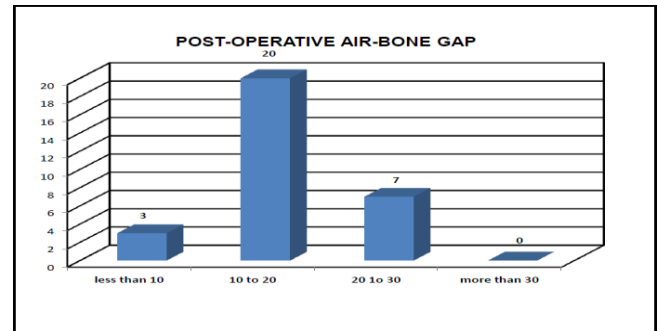


Figure 3: Postoperative improvement in air-bone gap.

After 1 year of follow up, 23 patients had a normal tympanic membrane, 3 patients had residual perforations, 2 had retracted grafts and 2 had myringitis.

According to the American Academy of Otolaryngology-Head and Neck Surgery guidelines, a successful hearing result is the one with post-operative air-bone gap of 20 decibels or less. Hence, by this standard our success rate is 77 percent and in all of our patients we have air-bone gap closure to below 30 decibels.

Extrusion rate was zero percent.

DISCUSSION

The commonest type of ossicular chain erosion encountered is necrosis of long process of incus because of its anatomical position and the course of its blood supply. Various surgical techniques and materials have been used for ossicular chain reconstruction since 1950, but still there is no standardized technique and ideal material accepted worldwide. Three general classes of prosthesis are used today: autograft, homograft and allograft.

Autograft prostheses include ossicles (incus, malleus), cartilages (septal, tragal), cortical bone. Advantages of autograft prostheses include a very low extrusion rate, no risk of transmitting disease, biocompatibility, and no necessity for reconstitution. Displacement, complete absorption, small remnant size, and possibility of harbouring microscopic disease have been cited as potential disadvantages to their use. Hence we had chosen autologous incus as the material for ossicular reconstruction. In our study, we have taken the cases where malleus and stapes both are present and there was no need of canal wall down procedures. This ruled out any acoustic variation for comparison of the result with normal hearing mechanism.

According to the American Academy of Otolaryngology-Head and Neck Surgery guidelines, a successful hearing result is the one with post-operative air-bone gap of 20

decibels or less. The results were analyzed with respect to above guidelines and out of 30 patients, 23 patients had post-operative air-bone gap closed to less than 20 decibels (76.67%) and all 30 patients had post-operative air-bone gap less than 30 decibels.

Bauer (2000)¹ studied results of ossiculoplasty in over 785 cases over 34 years between 1964 and 1998. Out of these, 41 cases were the cases where autologous incus was used. The average post-operative air-bone gap was 18.1 decibels. 23 percent of the cases had air-bone gaps equal to or smaller than 10 decibels. 67 percent of the cases had air-bone gap equal to or smaller than 20 decibels.

Rondini-Gilli (2001)² studied about 200 cases of ossiculoplasties in which about 23 cases were operated using incus autografts. In these patients, the residual air-bone gap was equal to 23 decibels (Standard deviation 12.5 decibels) with 57 percent of patients of had air-bone gap less than 20 decibels at 12 month follow up.

22 patients had healthy graft with 8 patients having complications of myringitis, retracted graft or residual perforation. All the patients with retracted or residual perforation had oedematous middle ear mucosa. Only 3 out of 8 (37.5%) patients having middle ear oedematous mucosa had post-operative healthy graft. Out of 30, 10 patients had Eustachian tube dysfunction. Only 5 out of 10 patients had postoperative healthy graft, 3 patients had residual perforation and 2 had retracted drum. Rest 20 patients having healthy Eustachian tube functioning had post-operative healthy grafts.

Dornhoffer (2001)³ reported that the status of the middle ear mucosa was likewise found to influence the hearing results. On the otologic database, mucosa was described as normal (n=65), thickened (n=64), or fibrotic (n=71), with fibrotic defined as significant adhesions, scar bands, or denuding of the mucosa during surgery. The postoperative PTA-ABGs for these types of middle ear mucosa were 10.7±5.7, 11.8±6.6, and 18.0±9.7 db, respectively. Although there was a trend towards worse hearing results with mucosal thickening, only fibrosis was statistically significant in predicting a worse outcome (p < 0.05).

Manning (1987)⁴ investigated the prognostic value of Eustachian tube function in the cases of tympanoplasty. In 49 ears (78%), the graft took; of these, 33 had good middle-ear function, 8 developed persistent or recurrent otitis media, and 8 had severe retraction or atelectasis. There was a significant association (p less than 0.01) between outcome and preoperative tubal function as determined by combining the active and passive function parameters

On the basis of otorrhea, perforation of tympanic membrane, ossicular status, presence of middle ear granulation and previous surgery, we calculated MER index for the patients and correlated it with our results.

Table 1: Categorization of patients with MER index.

MER index	Cases	Condition of graft			Hearing results (post op air-bone gap)	
		Healthy	Residual perforation	Retracted	<20 db	>20 db
1-3	25	23	1	1	20	5
4-6	5	2	2	1	3	2
7-12	Nil	Nil	Nil	Nil	Nil	Nil

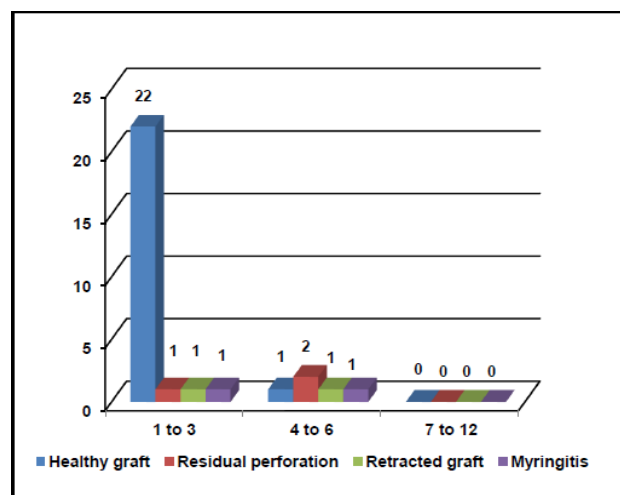


Figure 4: Post-operative otoscopic findings.

The results shows that 2 out of 5 patients who had higher Middle ear risk index had post-operative air-bone gap of more than 20 decibels (40 percent) whereas out of 25 patients with lower Middle ear risk index only 5 had post-operative air-bone gap of more than 20 decibels (20 percent). The difference was statistically significant between the two groups (P < 0.05).

The results also show that out of 5 patients who had higher Middle ear risk index, only two had healthy graft (40 percent) whereas out of 25 patients with lower Middle ear risk index only one patient had residual perforation and one case had a retracted graft; 23 out 25 patients had healthy graft (92 percent).

Kumar and Madkikar (2011)⁵ studied 50 patients (64 ears) with unilateral or bilateral perforation of tympanic membrane for a period of 2 years with the objective to assess the result of surgical treatment of tubotympanic chronic supportive otitis media and its relation to the Middle Ear Risk Index. According to this MERI Index carried out for the 50 ears studied, suggested risk categories and no. of ears that fall in each category and result of tympanoplasty according to MERI score was assessed. It was observed that maximum number of ears 36 (72%) fall under MERI 1-3 i.e. mild disease followed by 12 (24%) ears with MERI score of 4-6 i.e. moderate disease and then by 2 (4%) ears with MERI score of 7-12

i.e. Severe disease. On comparing the result of tympanoplasty it was observed that ears which fall under risk category of MERI 1-3 i.e. mild disease was best i.e. 86% followed by MERI 4-6 moderate disease i.e. 75%, ears with MERI score of 7-12 i.e. severe disease none of the ear accepted the graft.

There were no cases where extrusion of incus occurred. Bauer (2000), Schuring and Lippy (1983), O'Reilly (2005)⁶, Li HZ (2008)⁷, Naragund (2011)⁸ and Nikoloau (1992)⁹ reported zero percent extrusion rate of reshaped autologous incus. Ceccato (2005)¹⁰ reported one percent incidence of incus extrusion. Similarly, Rondini-Gilli (2000) reported 2 cases of incus extrusion in series of 200 cases (1 percent). Nikoloau (1992) reported absorption of incus in 5 out of 40 cases (12.5 percent). Li HZ (2008) reported 2 cases in group of 68 patients where reshaped incus had got displaced.

CONCLUSION

Autologous incus is an excellent interposition graft for ossiculoplasty. There is no risk of transmission of disease and no extra cost involved. Pre-operative air-bone gap is a very good indicator for predicting ossicular discontinuity. As a dictum, an air-bone gap more than 45 decibels hints upon discontinuity in ossicular chain. Average closure in air-bone gap (gain) in our patients is 25.9 decibels with average pre-operative and post-operative air-bone gap being 47.70 decibels and 16.9 decibels. Extrusion rate was zero percent. Higher values of Middle Ear Risk Index, oedematous middle ear mucosa and Eustachian tube dysfunction are poor prognostic factor for success of ossiculoplasty.

Funding: No funding sources

Conflict of interest: None declared

Ethical approval: The study protocol was approved in Human Research Ethics Committee

REFERENCES

1. Bauer M. Ossiculoplasty: autogenous bone grafts, 34 years experience. Clin Otolaryngol Allied Sci. 2000;25(4):257-63.
2. Rondini-Gilli E, Mosnier I, Julien N, Gouin JM, Aïdan P, Rufat P, et al. Predictive factors of outcome in 220 ossiculoplasties in adults. Ann Otolaryngol Chir Cervicofac. 2001;118(5):283-90.
3. Dornhoffer JL, Gardner E. Prognostic Factors in Ossiculoplasty: A statistical staging system. Otol Neurotol. 2001;22(3):299-304.
4. Manning SC, Cantekin EI, Kenna MA, Bluestone CD. Prognostic value of eustachian tube functions in pediatric tympanoplasty. Laryngoscope. 1987;97(9):1012-6.
5. Kumar N, Madkikar NN, Kishve S, Chilke D, Shinde KJ. Using middle ear risk index and et function as parameters for predicting the outcome of tympanoplasty. Indian J Otolaryngol Head Neck Surg. 2012;64(1):13-6.
6. O'Reilly RC, Cass SP, Hirsch BE, Kamerer DB, Bernat RA, Poznanovic SP. Ossiculoplasty using incus interposition: hearing results and analysis of the middle ear risk index. Otol Neurotol. 2005;26(5):853-8.
7. Li HZ, Gong SS. Observation of bridging operation by an autogenous incus in the ossiculoplasty. Zhonghua Er Bi Yan Hou Tou Jing Wai Ke Za Zhi. 2008;43(10):746-50.
8. Naragund AI, Mudhol RS, Harugop AS, Patil PH. Ossiculoplasty with autologous incus versus titanium prosthesis: A comparison of anatomical and functional results. Indian Journal of Otology. 2011;17(2):75-9.
9. Nikolaou A, Bourikas Z, Maltas V, Aidonis A. Ossiculoplasty with the use of autografts and synthetic prosthetic materials: a comparison of results in 165 cases. J Laryngol Otol. 1992;106(8):692-4.
10. Ceccato SB, Maunsell R, Morata GC, Portmann D. Comparative results of type II ossiculoplasty- incus transposition and titanium PORP. Rev Laryngol Otol Rhinol (Bord). 2005;126(3):175-9.

DOI: 10.5455/2349-3259. ijct20150504

Cite this article as: Bihani A, Dabholkar J. Use of incus as an interposition graft in ossiculoplasty for type IIb tympanoplasty. Int J Clin Trials 2015;2:43-6.