

Original Research Article

A prospective study on the role of epidural steroidal injections in backache with radiculopathy

Akhil Gupta*, Nitin Choudhary, Fareed Hussain Malik

Department of Orthopaedics, GMC, Jammu, Jammu and Kashmir, India

Received: 12 February 2021

Accepted: 03 April 2021

***Correspondence:**

Dr. Akhil Gupta,

E-mail: akhilgupta.ortho@gmail.com

Copyright: © the author(s), publisher and licensee Medip Academy. This is an open-access article distributed under the terms of the Creative Commons Attribution Non-Commercial License, which permits unrestricted non-commercial use, distribution, and reproduction in any medium, provided the original work is properly cited.

ABSTRACT

Background: Low backache (LBA) with lumbosacral radiculopathy is the most challenging musculoskeletal problem for its therapeutic management and cause of LBA with radiculopathy is a prolapsed disc. Epidural steroidal injection (ESI) are used in the management of the patients with sub-acute or chronic LBA with radiculopathy, not responding to conservative treatment. The most common cause being, lumbar disc disease, is confirmed via magnetic resonance imaging having high sensitivity and specificity. The aim of study was to check the efficacy of ESI in patients of sub-acute or chronic low backache with radiculopathy due to herniated disc.

Methods: The study was conducted over 200 patients reporting our OPD during Dec 2017- Feb 2018 with complaints of LBA with radiculopathy, not responding to conservative treatment. Maximum of 3 ESI were given with two weeks of interval in between. The patients were assessed using VAS scoring system.

Results: 77.5% patients got improvement in symptoms, according to the VAS scores, while 22.5% patients got very little relief or no relief at all. 53.5% patients got significant improvement with the first dose of injection itself. Patients had a good relief from radicular pain immediately; however, sense of satisfaction of well-being was only after few months.

Conclusions: Though results supported the relative benefit of epidural steroid, however conservative management should also be recommended as initial treatment. ESI procedure is effective in treating patients of sub-acute LBA with radiculopathy and is recommended before a patient is considered for surgery.

Keywords: Epidural steroid, Low back ache, Visual analogue scale, Efficacy

INTRODUCTION

Radiculopathy is defined as the pain along the dermatomal distribution of spinal nerve root, often related to the direct affection of nerve tissue. Low backache is the most frequently attended complaint in an orthopaedic OPD. LBA with lumbosacral radiculopathy has always proved to be most challenging musculoskeletal issue in a clinic and even more so because of its therapeutic management.¹ Low backache could be acute, sub-acute or chronic. By definition, acute pain will sustain up to 4 weeks, a sub-acute pain will sustain for 4-12 weeks and a chronic pain will last for more than 3 months. Prolapsed disc is found to be most common cause of low back radiculopathy, with around 90% patients presenting the

same, while spinal stenosis and facet joint arthropathy coming next.² Rheumatoid arthritis, infections, fractures and tumours are also common among such cases etc. Inflammation of nerve root and nerve root compression by the herniated disc is therefore thought to be an important factor for developing radiculopathy, but radiculopathy can occur in absence of nerve compression also.³

For effective treatment of patients having sub-acute or chronic low back ache with radiculopathy, various treatment modalities may be available, but epidural steroid injections or ESI is considered to be one among the less invasive techniques.⁴ Since, back pain in a disc disease may not be only because of compression on neural elements, but may also be due to chemical

inflammation, other treatments involving surgery aim at decompressing the pressure on neural elements and conservative treatments aim to combat the chemical radiculitis.⁵ MRI scan is a widely available diagnostic and confirmatory tool now, and therefore a disc lesion in MRI may influence the surgeon's decision to operate and remove the offending disc. However, many a times, patients may not be actually requiring surgery and can be treated using non-operative procedures like ESI.

This study aims at establishing the effective outlay of ESI technique be used in J and K and fills up an important gap in recording such research outcomes for better and effective mode of treating LBA.

METHODS

The present study was conducted in the department of orthopaedics, government medical college Jammu, from October 2017 to March 2019, after obtaining due ethical approval, where 200 patients were inducted for the study. Informed consent was also taken from patients before the start of the study.

Inclusion criteria

Inclusion criteria for study included patients above 18 years of age were included. All symptomatic patients with sub-acute/chronic low back pain, with disc herniations, having MRI findings as positive, were included.

Exclusion criteria

Exclusion criteria for the study excluded pregnant females or ongoing breast-feeding females. Patients with underlying malignancies. Patients who had not given consent for the procedure. Patients under heart failure or CHF. Patients having any bleeding disorder or on anticoagulation therapy and/Or, any condition that hindered early mobilization of the patient.

Initially, patients presenting with LBA radiating to one or both gluteal regions and posterior aspect of thighs in combination with worsening conditions of pain while coughing and sneezing were evaluated. The diagnosis was further confirmed with radiographic imaging. Lateral and anteroposterior plain radiographs of lumbar spine were taken to evaluate osseous anatomy and alignment. Later, MRI findings were evaluated to confirm and rule out the disc related or other possible causes of low back pain like infections or tumours of spine and/or intra-abdominal visceral causes. All such causes may have bearing on the procedure and treatment and thus possible inclusion into the study. Primarily, hematological (Hb, TLC, DLC, ESR, platelet count) and Biochemical (blood sugar, blood urea, serum creatinine) were undertaken. Taking their history and physical examination in consideration, patients were selected for 'conservative management up-to 4 weeks period' as well as for direct

ESI. Patient education was made an essential part of treatment in both the groups.

Conservative management

Patients, planned for conservative treatment, were treated with non-steroidal anti-inflammatory drugs, muscle relaxants and bed rest for a period of two to three weeks. Physiotherapy was also initiated in due course of time, with stretching, core muscle strengthening and trunk stabilization exercises.

Epidural steroid injections

Epidural steroid injections are given by 3 routes: transforaminal approach, caudal approach, and interlaminar approach. We preferred interlaminar approach in our patients as this approach was easy for both patients as well as the doctor and delivered drug closer to the site of ailment. All the patients planned for the injection were kept fasting 6 hours prior to the procedure after proper lab investigations and anaesthetic checkups. All resuscitative machines and anaesthesia equipment were kept stand by to be ready for any possible adverse reactions. An 18G intravenous canula was used for venous access and ringer lactate was started. The procedure was done in sitting position in the operation theatre, under all aseptic precautions. Disc level was located by surface anatomy without any fluoroscopy guidance. Two cc of 2% lignocaine was infiltrated in the skin and subcutaneous tissues. An 18G epidural needle was inserted in the midline with the bevel upwards and the stylet in position between the spinous process at the desired level. Interspinous ligament was pierced and needle advanced with loss of resistance being carried out at intervals. Just after penetrating ligamentum flavum, the epidural space was entered and loss of resistance was positive, then 80mg of reconstituted methylprednisolone was injected into the epidural space along with 10 ml of 0.5% bupivacaine. After the procedure, the patient was kept under observation for 30 minutes with multiple channels monitoring (MCM). Patient was checked for any motor or sensory block and then was shifted to ward. Patient was advised to lie in supine position for 24 hours and was given orally tablet cefuroxime 500 mg twice daily along with tablet diclofenac 75 mg for two days during post injection period. Patient was kept admitted in the hospital over-night and discharged next day.

Follow-up was done at 2 weeks, 4 weeks and 3 months. Patients was assessed for lower back and lower extremity pain on the basis of VAS score from 0 (no pain) to 10 (worst pain possible). If a patient subjectively reported a decrease in pain in net follow-up, no more injections were administered. if the patient reported slight decrease in pain or no relief, second injection was given in the similar manner and patient called for the next follow up after 2 weeks. Again, assessment was done based on VAS score at net follow up at 4 weeks and third injection was given. Patients of low backache with radiculopathy

not responding to even three doses of epidural steroids were then considered for surgery.

RESULTS

Out of the 200 patients, who were administered the defined course of treatment, 155 (77.5%) patients got improvement in symptoms, according to the VAS scores (Figure 1). 107 (53.5%) patients got significant improvement with the first dose of injection itself. 34 (17.0%) patients got improvement of significant nature upon second dose, while only 14 (7.0%) patients got satisfactorily improved upon third dose of injections. 45 (22.5%) patients got very little relief or no relief at all, even after three doses of epidural steroid injections (Figure 1).

Upon retrospective generalization, it was found that out of the 155 patients who showed improvement upon present procedures, 117 patients had sub-acute pain while 38 patients suffered from chronic pain. Similarly, out of the 45 patients, not responding to the treatment, 41 patients suffered from chronic pain. This showed the effectiveness of the procedure/treatment only on sub-acute low backache with radiculopathy.

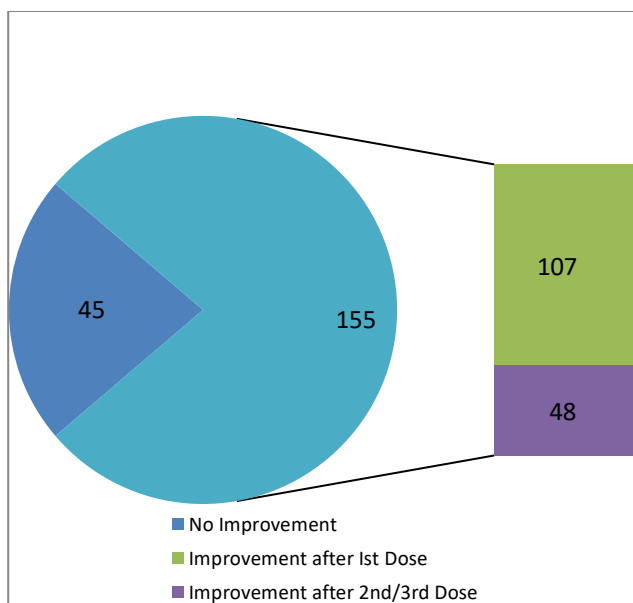


Figure 1: Patients showing improvement upon epidural steroid injections.

DISCUSSION

Sciatica due to lumbar intervertebral disc herniation is one of the most common cause of radicular pain in an adult working population.⁶ A plethora of treatment modalities exist for this common problem; many patients have a tendency to avoid surgery considering its associated risk factors and cost. Lumbar epidural steroid injection is a reasonable non-surgical option available in such situation. We have number of studies that have compared epidural steroid injection with discectomy for

the treatment of lumbar disc herniation.⁷ There are only a few studies throw light on conservative management of lumbar disc herniation. We intended to study epidural injection in the management of sub-acute or chronic low backache with radiculopathy. Back pain radiating to lower limb is still, one of the unrewarding problems to deal with in clinical medicine. Among the various factors of low back pain, only those syndromes associated with neurological compression of the cauda equine of nerve roots, have reasonably well understood clinical presentation

Among the galaxy of causative factors, both spinal and extra-spinal, the most common cause of low backache seems to be the lumbar disc disease. The condition is increasing in number in our society and is associated with considerable morbidity and significant disability. The disc gives the spine the mobility and acts as shock absorber. The diagnosis of level and degree of protrusion or prolonged disc based upon clinical findings was confirmed by magnetic resonance imaging having high sensitivity and specificity. The mode of conservative management is bed rest, skin tractions, physiotherapy, exercise therapy, drug therapy and epidural steroid infiltration. Operative intervention indicated in patients.⁸ However, the final effect of epidural steroid treatment on the predominant symptom and satisfaction were similar after adjusting for other predictors of outcome. Thus, our results are partly comparable to several randomized trial regarding the volume of injectate; Winnie et al have found that high volumes have no benefit over the low volume.⁹ However, it was found that minimal volume should not be less than 4ml. the more volume of drug helps in flushing the inflammatory mediators and breaks the adhesions too.¹⁰ Several studies are in favour of epidural steroid injections in LBA with radiculopathy. According to Bogduk, out of 40 studies carried out on more than 4000 patients regarding epidural steroid injections, 36 studies recommended their use in the treatment.¹¹ Another study carried out by Wani et al over 150 patients with a follow up of 2 years found overall success rate of 69%.¹²

We observed that after a dose of epidural steroid injections, the patients had a good relief from radicular pain immediately following the injection we noticed that sense of satisfaction of well-being was only after few months. So, considering this observation we can say that the full response of epidural steroid often was delayed. The quick relief can probably attribute to the local anesthetic that is injected along with the steroid.

Though our results support the relative benefit of epidural steroid for properly selected patients, this does not mean that conservative management should be no longer recommended as initial treatment. Conservative treatment for at-least 4 to 6 weeks can be recommended for patients with an inter-vertebral disc herniation without significant disability.

CONCLUSION

Epidural steroid injection is safe, cost effective and minimally invasive method of treating patients of sub-acute or chronic low back ache due to herniated disc. The procedure is more effective in treating patients of sub-acute LBA with radiculopathy rather than with chronic issue. We recommend epidural steroid injection as an effective mode of treating LBA with radiculopathy in patients not responding to conservative method of treatment.

Funding: No funding sources

Conflict of interest: None declared

Ethical approval: The study was approved by the Institutional Ethics Committee

REFERENCES

1. Frymoyer JW, Cats-Baril WL. An overview of the incidence and costs of low back pain. *Orthop clin North Am.* 1991;22:263-71.
2. Tarulli AW, Raynor EM. Lumbosacral radiculopathy. *Neurol Clin.* 2007;25:387-405.
3. Deyo RA. Real help and red herrings in spinal imaging. *N Engl J Med.* 2013;368:1056-8.
4. Sicard A. Less injections medicamentuses extradurales par voie sacro-coccygienne. *Cr Soc Biol Paris.* 1901;53:369.
5. Rozenberg S, Duborg G, Khalifa P. Efficacy of epidural steroids in low back pain and sciatica: a critical appraisal by a French task force of randomized trials. *Rev Rhum.* 1999;66:79-85.
6. Rothoerl RD, Woertgen C. When should conservative treatment for lumbar disc herniation be ceased and surgery considered? *Neurosurg review.* 2002;25:162-25.
7. Wang Jeffrey C, Lin Eric, Darrel S. Epidural injections for the treatment of symptomatic lumbar herniated disc, 2002;15:269-72.
8. Walker BF. The prevalence of low back pain: a systematic review of the literature from 1996 to 1998. *J Spinal Discord.* 2000;13:205-17.
9. Winnie AP, Hartman JT, Meyers Jr HL, Ramamurthy S, Barangan V. Intradural and Etradural corticosteroids for sciatica. *Anesth Analg.* 1972;51:990-93.
10. Botwin KB, Gruber RD, Bouchlas CG. fluoroscopically guided lumbar transformaminal epidural steroid injections in degenerative lumbar stenosis. *Am J phys Med Rehabil.* 2002;881:89-905.
11. Bogduk N. Spine update-Epidural steroids. *Spine.* 1995;7:845-8.
12. Wani A, Habib M, Tantray M. Our experience with epidural steroid injections in the management of low back pain and sciatica. *Internet J Orthop Surg.* 2012;9:2.

Cite this article as: Gupta A, Choudhary N, Malik FH. A prospective study on the role of epidural steroidal injections in backache with radiculopathy. *Int J Clin Trials* 2021;8(2):125-8.